

DOI: <https://doi.org/10.59913/dagr.2023.12359>

Estradiol and testosterone hormones as a method for sex determination of Siberian sturgeon (*Acipenser baerii*) from Zhrebchevo Dam Lake, Bulgaria

ATANASOFF, Alexander¹ – RUSENOV, Anton¹ – ZAPRYANOVA, Dimitrinka¹ – LAZAROV, Lazarin¹ – URKU, Cigdem^{2*} – NIKOLOV, Galin³

¹Trakia University, Faculty of Veterinary Medicine, 6014 Stara Zagora, Bulgaria

²Istanbul University, Faculty of Aquatic Science, 34134 Istanbul, Türkiye

³Trakia University, Faculty of Agriculture, 6014 Stara Zagora, Bulgaria

*corresponding author: curku@istanbul.edu.tr

Abstract

Determination of the gender in sturgeon is very important in fish farmers, as sex is one of the main factors that determine aim of cultivating them. One of the method for maturation monitoring of sturgeons is steroid hormone analysis. On this base the current study used estradiol and testosterone hormones to determine the gender of 2-3-year-old Siberian sturgeon (*Acipenser baerii*) cultivated in sturgeon broodstock farm located in the Zhrebchevo Dam lake, Bulgaria. The serum concentrations of circulating reproductive hormones found in the both sex were similar to the hormonal profiles in previously reports. The results were confirmed also by histological examination, which showed pre-vitellogenic stage (Stage I) in female and maturity (Stage V) at the male individuals. The findings indicate the force of current steroid hormones as a method for sex determination. In conclusion, analysis of circulating reproductive hormones may be a useful method in early determining the sex of Siberian sturgeon.

Keywords: determination of gender, 17 β -estradiol, sturgeon, testosterone

Introduction

In Bulgaria, sturgeon production started since the end of the last century (NIKOLOVA et al., 2018). Based on export data from the Convention on International Trade in Endangered Species of Wild Fauna and Flora and production

DOI: <https://doi.org/10.59913/dagr.2023.12359>

data from Food and Agriculture Organization of the United Nations for the period 2016-2020, Bulgaria produced mainly Siberian sturgeon (22%) (EUMOFA, 2023). Early differentiation of the gender in this species is very important in fish farmers, as sex is one of the main factors that determine cultivating them for caviar or meat in the future (RUSENOV et al., 2019). Generally, females are raised until they start to produce caviar, which can take at least six years (JAHRL, 2013). In contrast males are usually bred within 3-4 years mainly for meat and an insignificant part for breeding (Park et al., 2020). In this regard, several invasive and non-invasive methods have been developed to early determine the sex of these sturgeon species. The most common of them include endoscopy (MUNHOFEN et al., 2014), laparoscopy (FALAHATKAR et al., 2011), ultrasound (RUSENOV et al., 2019), vitellogenin mRNA expression (Park et al., 2020) and steroid hormones (ABBASI et al., 2016), Therefore the purpose of this study was to examine serum steroid hormone levels and also gonad development as evidence of gender in Siberian sturgeon.

Material and methods

Fish samples

In present study, twelve Siberian sturgeon (*Acipenser baerii* BRANDT, 1869) aged < 3 years and in the early stage of sexual maturation (weight 2210.82±31.41 g) were obtained from sturgeon broodstock farm, located in the Zhebchevo Dam Lake, Bulgaria (42.587996, 25.898514), where were reared in net-cages reflecting the ambient condition of the reservoir.

Blood samples and hormone analysis

Blood samples were drawn from the vena caudalis using a needle (20G). The collected samples (approx. 1 ml) were centrifuged at 3000 rpm for five minutes (Ohaus FC5515, Ohaus Corp., USA) at room temperature. After coagulation, the obtained serum was immediately removed, placed into a clean Eppendorf microcentrifuge tube and stored at -20°C until analysed. Serum 17β-estradiol (E2) and testosterone (T) analyses were conducted with Elisa analyser, HumaReader HS (Human GmbH, Wiesbaden, Germany) and its measurement AccuBind® Elisa kit (Monobind, Inc., USA).

Determination of sexual maturity stages

Gonad biopsy samples were taken during an ultrasound examination in order to determine the gonad stage. The samples of gonad tissue were fixed in 10% buffered formalin and processed for paraffin embedding. Paraffin embedded sections, 4-5 μm thick, were stained with haematoxylin and eosin (H&E) and examined by light microscopy (ALLEN, 1992). The sexual maturity stage of the gonad was identified

DOI: <https://doi.org/10.59913/dagr.2023.12359>

according to WILDHABER et al. (2007). The mean oocyte diameter (μm) was measured by Olympus C-mount camera adapter (U-TV0.63XC, Olympus Ltd, Co., Japan).

Statistical analysis

The statistical evaluation of the data obtained from the experiment was made using the software Statistica v.10 (STATSOFT INC., USA, 2010). The results were presented as mean and standard deviation of the mean (Mean \pm SD).

Results and discussion

The present study used a non-lethal approach to determine the sex and reproductive stage of Siberian sturgeon by using some of steroid hormones, to wit 17β -estradiol and testosterone. In sturgeon species, the steroid hormones are unrecognizable until sex differentiation occurs (YOUNESZADEH-FASHALAMIET al., 2018).

In the current investigation, there were differences in serum 17β -estradiol concentration among pre-vitellogenic (stages I) and cortical alveoli (stage II). No serum E2 was found in stage I, while female in stage II was recorded (0.35 ± 0.09 ng/ml) (Figure 1). However, E2 was found to be higher in female juvenile sturgeon than in male. This may be due to the fact that unlike mature male, females in the pre-vitellogenic stage do not secrete gonadotropin hormone (GTH). The GTH is thought to be responsible for inducing vitellogenesis, as well as at a later stage to regulate final ovarian maturation and ovulation. Hence, it can be concluded that the female individuals at the stage I reproduction process still have relatively low or lack pituitary concentrations and functional receptors of GTH. In other hand, female vitellogenin (VTG) starts to produce in response to increasing estradiol levels during development of oocytes, while in male is low or lacks VTG. These data are supported from earlier reports in other sturgeon species, where plasma or serum 17β -estradiol level increased from the pre-vitellogenic to the vitellogenesis stage and reached its highest level in the post-vitellogenic stage (WEBB et al., 2002; WILDHABBER et al., 2007; HOSSEINZADEH et al., 2013; Carolyn et al., 2016; YOUNESZADEH-FASHALAMI et al., 2018). Actually, the lack of huge differences in E2 values between the both sex was expected, as immature individuals are known to have the lowest basal levels (WHEELER et al., 2016), in contrast to female Siberian sturgeon in stage IV, which correspond to the maximum incorporation of vitellogenin (PELISSERO et al., 1989).

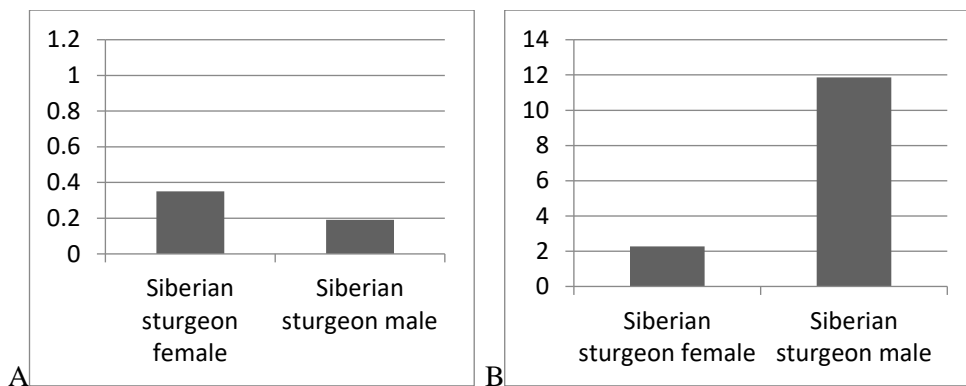
DOI: <https://doi.org/10.59913/dagr.2023.12359>

Figure 1. Serum 17β-estradiol (A) and testosterone (B) in Siberian sturgeon (Mean ± SD).

The testosterone plays the main role in spermatogenesis and therefore may be used to differentiate between immature female and male Siberian sturgeon, but only in the case the concentration in blood above 4 ng/ml (ABBASI et al., 2016). The mean serum testosterone concentration of Siberian sturgeon was found to be higher in males (11.85±0.71 ng/ml) than in females (2.28±0.02 ng/ml). Like 17β-estradiol, serum testosterone value showed an increasing trend with the stage. In study again with female sturgeon in pre-vitellogenic stage treated with testosterone implants was determined higher levels of gonadotropin. It could be suggested that it had strong positive feedback between testosterone and pituitary but without further effect on ovarian development (MOBERG et al., 1995).

The histological data on oocytes showed that the Siberian sturgeon, like the bester sturgeon, white sturgeon, shortnose sturgeon, sterlet and many other sturgeons, has a heterogeneous asynchronous ovarian development in the early stage of reproduction (FALAHATKAR, 2015). In the current study, histological analysis confirmed that females were at the pre-vitellogenic stage (Stage I), according to the classification of WILDHABER et al. (2007). Oocytes (average diameter 200-300 μm) were located at the periphery of the ovarian lamellae (Figure 2). Furthermore, the development of oocytes was accompanied by a decrease in the concentration of testosterone and an increase in the concentration of 17β-estradiol. This is in complete agreement with a previous study in the same species (MOSYAGINA and ZELENNIKOV, 2016).

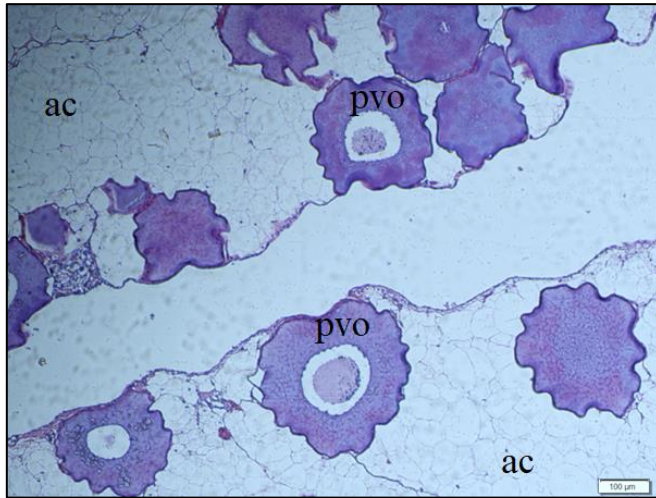


Figure 2. Histology of Siberian sturgeon ovarium. Pre-vitellogenic oocytes (Stage I) at the periphery of lamellae. **(ac)**: adipocytes **(pvo)**: pre-vitellogenic oocytes

Separately, the ooplasm surrounding thick basal lamina showed strong basophilia and the nucleus contained many nucleoli close to the nuclear membrane (Figure 3).

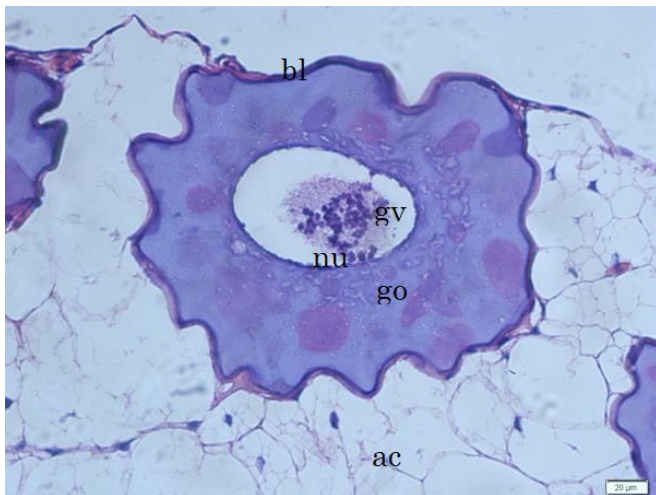


Figure 3. Pre-vitellogenic oocyte **(nu)**: nucleoli, **(gv)**: germinal vesicle, **(bl)**: basal lamina, **(go)**: granular ooplasm, **(ac)**: adipocytes

The histological section of Siberian sturgeon testis showed maturity stage V. Large testicular tubules were filled by elongate, intensely basophilic heads of mature spermatozoa (Figure 4). In the Siberian sturgeon male, the intensification of the activity of steroid secretory cells was indirectly determined by the stage, which is

DOI: <https://doi.org/10.59913/dagr.2023.12359>

connected by an increase in the concentration of testosterone in blood (MOSYAGINA and ZELENNIKOV, 2016).

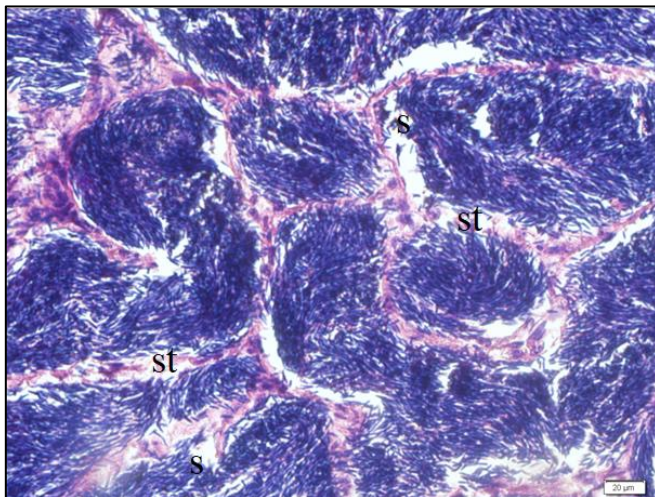


Figure 4. Histology of genderin Siberian sturgeon testis. The rod-likeheads of abundant mature spermatozoa (stage V) (**arrow**) filling large seminiferous tubules (H&E) (**st**): seminiferous tubule, (**s**): spermatozoa

Using serum E2 and testosterone concentrations, we were able to identify gender in Siberian sturgeon with high accuracy similar to other methods in same species such as endoscopy (MUNHOFEN et al., 2014), laparoscopy (FALAHATKAR et al., 2011), ultrasound (RUSENOV et al., 2019).

In conclusion, results of the present study indicate that the determination of steroid hormone levels may be indicative of early gonadal maturation, and subsequent histological examination are useful and effective methods for determining the stage of reproduction in 2-3-year-old Siberian sturgeon.

Acknowledgements

This work has been supported by Trakia University, Faculty of Veterinary medicine, Research Grant Contract No. 07/2017.

References

ABBASI, N. – NOORI, A. – TOLOUIE GUILANI, M.H. – KALVANI-NEITALI, B. (2016): The study of seasonal steroid hormones in male Siberian sturgeon

DOI: <https://doi.org/10.59913/dagr.2023.12359>

(*Acipenser baerii*) for determining gonadal development stages. J Microbiol Biotech Food Sci. 6(2): 764-766. <https://doi.org/10.15414/jmbfs.2016.6.2.764-766>

ALLEN, T. (1992): Hematoxylin and eosin. In: PROPHET, E. – MILLS, B. – ARRINGTON, J. – SOHIN, L. (eds) Armed forces institute of pathology laboratory methods in histotechnology. American Registry of Pathology, Washington, DC: 53-58.

EUMOFA (2023): Sturgeon meat and other by-products of caviar. Publications Office of the European Union, Brussels, Belgium: 1-27.

FALAHATKAR, B. – TOLOUEI, M. – FALAHATKAR, S. – ABBASALIZADEH, A. (2011). Laparoscopy, a minimally-invasive technique for sex identification in cultured great sturgeon (*Huso huso*). Aquaculture 321: 273-279. <https://doi.org/10.1016/j.aquaculture.2011.08.030>

FALAHATKAR, B. (2015): Endocrine changes during the previtellogenic stage of the great sturgeon (*Huso huso* Linnaeus, 1758). J. Appl. Ichth yol. 31: 830-838. <https://doi.org/10.1111/jai.12813>

HOSSEINZADEH, M. – IMANPOOR, M.R. – SHABANI, A. – NEKOUBIN, H. (2013): Seasonal changes in serum calcium and 17 β -estradiol levels in Persian sturgeon (*Acipenser persicus*). J Aquac Res Development 4: 159. <https://doi.org/10.4172/2155-9546.1000159>

JAHRL, J. (2013): Illegal caviar trade in Bulgaria and Romania - Results of a market survey on trade in caviar from sturgeons (Acipenseridae). WWF Austria and TRAFFIC, Vienna, Austria: 1-54.

MOBERG, G. – WATSON, J. – DOROSHOV, S. - PAPKOFF, H. - PAVLICK, Jr. R. (1995): Evidence for two sturgeon gonadotropins in *Acipenser transmontanus*. Aquaculture 135:17-39.

MOSYAGINA, M.V. – ZELENNIKOV, O.V. (2016): State of steroid secretory cells and concentration of gonadal steroid hormones in the blood plasma of Siberian sturgeon (*Acipenser baerii*) and sterlet (*Acipenser ruthenus*) during sex differentiation. J. Ichth yol. 56: 141-146. <https://doi.org/10.1134/S0032945215060107>

MUNHOFEN, J.L. - JIMÉNEZ, D.A. – PETERSON, D.L. – CAMUS, A.C. – DIVERS, S.J. (2014): Comparing ultrasonography and endoscopy for early gender identification of juvenile Siberian sturgeon. North American Journal of Aquaculture 76(1): 14-23. <https://doi.org/10.1080/15222055.2013.826765>

NIKOLOVA, L. – GEORGIEV, G. – BONEV, S. (2018): Morpho-physiological characteristics of Russian sturgeon reared in net cages. Bulgarian Journal of Agricultural Science 24(5): 865-870.

PARK, C. – GONG, S.P. – CHOI, Y.H. – KIM, K.H. – NAM, Y.K. (2020): Early gonadal maturation and vitellogenin mRNA expression in Siberian sturgeon (*Acipenser baerii*) cultured in a semi-closed water recirculating system in Korea. Journal of Animal Reproduction and Biotechnology 35: 279-288. <https://doi.org/10.12750/JARB.35.3.279>

DOI: <https://doi.org/10.59913/dagr.2023.12359>

PELISSERO, C. – CUISSET, B. – Le MENN, F. (1989): The influence of sex steroids in commercial fish meals and fish diets on plasma concentration of estrogens and vitellogenin in cultured Siberian sturgeon. *Aquat. Living Resour.* 2 (3): 161-168.

RUSENOV, A. – URKU, C. – ATANASOFF, A. – ZAPRYANOVA, D. – NIKOLOV, G. SPASOV, D. (2019). Early determination of gender in Siberian sturgeon (*Acipenser baerii*) using ultrasound and biopsy techniques. *Danub. Anim. Genet. Resour.* 4: 102.

WEBB, M.A.H. – FEIST, G.W. – FOSTER, E.P. – SCHRECK, C.B. – FITZPATRICK, M.S. (2002): Potential classification of sex and stage of gonadal maturity of wild white sturgeon using blood plasma indicators. *Trans Am Fish Soc* 131: 132-142. [https://doi.org/10.1577/1548-8659\(2002\)131<0132:PCOSAS>2.0.CO;2](https://doi.org/10.1577/1548-8659(2002)131<0132:PCOSAS>2.0.CO;2)

WHEELER, C. – ASHLEIGH, J.N. – GAIL, S.W. – JAMES, A.S. (2016): Using circulating reproductive hormones for sex determination of Atlantic sturgeon (*Acipenser oxyrinchus oxyrinchus*) in the Saco River estuary, Maine, *Conserv Physiol* 4(1): cow059. <https://doi.org/10.1093/conphys/cow059>

WILDHABER, M.L. – PAPOULIAS, D.M. – DELONAY, A.J. – TILLITT, D.E. – BRYAN, J.L. – ANNIS, M.L. (2007): Physical and hormonal examination of Missouri Rivers hovel nose sturgeon reproductive stage: a reference guide. *Journal of Applied Ichthyology* 23(4): 382-401. <http://dx.doi.org/10.1111/j.1439-0426.2007.00878.x>

YOUNESZADEH-FASHALAMIA, M. - SALATIA, A.P. – KEYVANSHOKOOHA, S. (2018): Comparison of proteomic profiles in the ovary of Sterlet sturgeon (*Acipenser ruthenus*) during vitellogenic stages. *Comparative Biochemistry and Physiology, Part D* 27: 23-29. <https://doi.org/10.1016/j.cbd.2018.04.006>